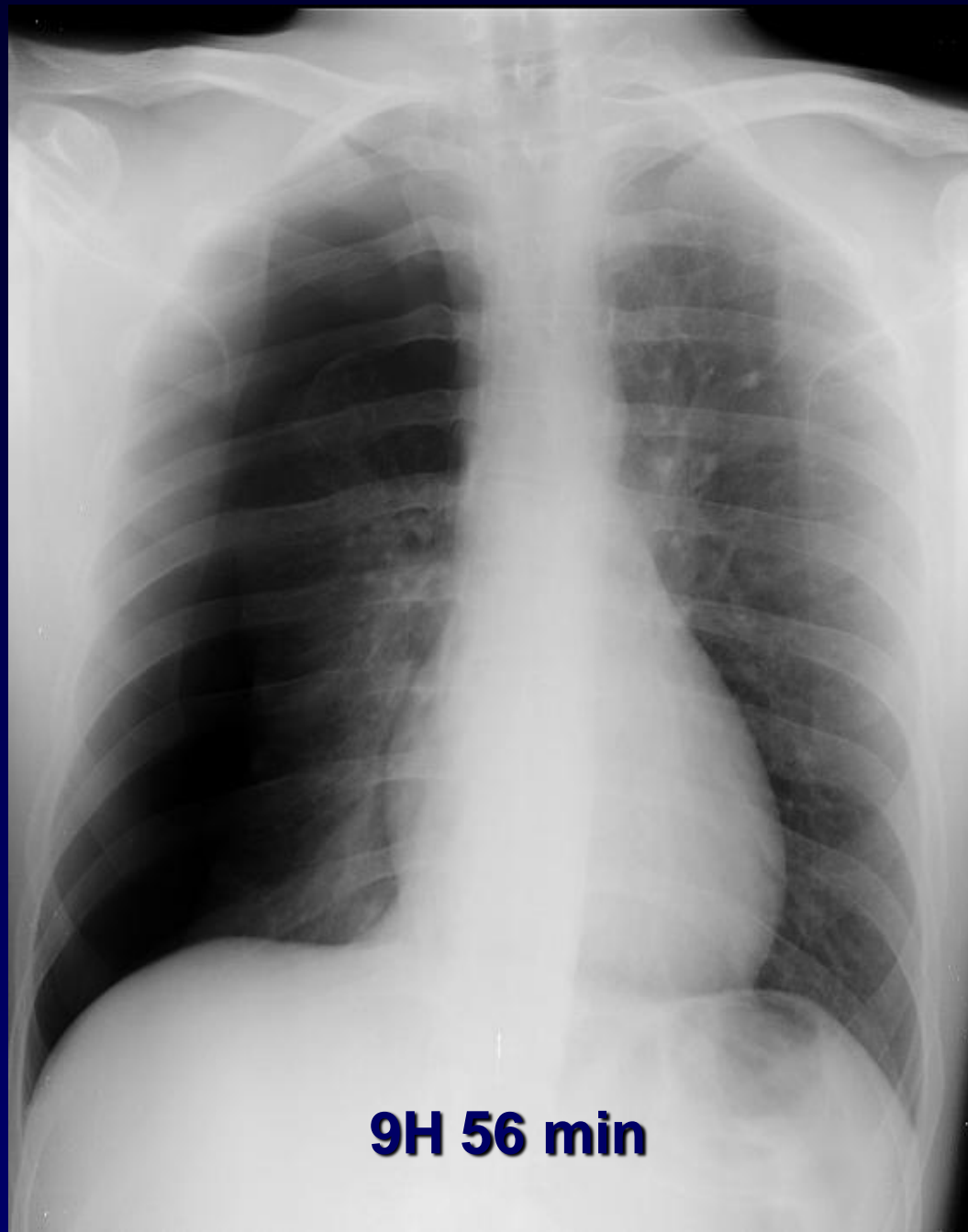
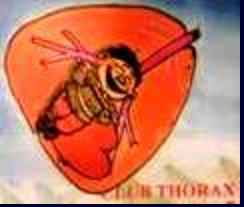



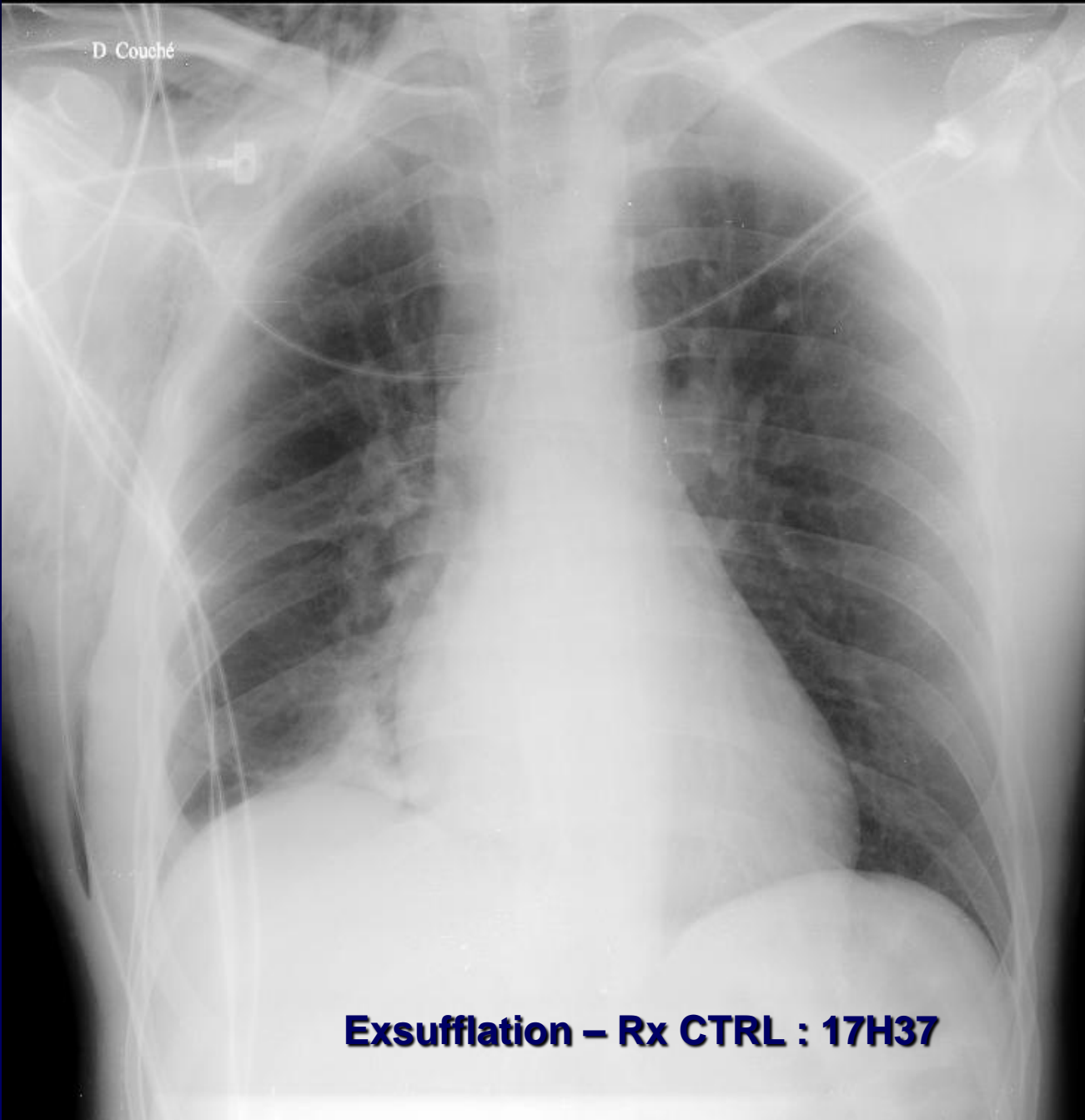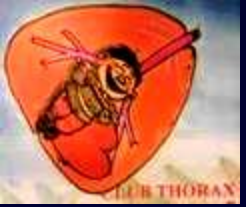
**M EL HAJJAM
P LACOMBE**

**Jeune médecin de 24 ans,
Tabagisme,
Joue au Saxophone,**

Douleur thoracique D+++



9H 56 min

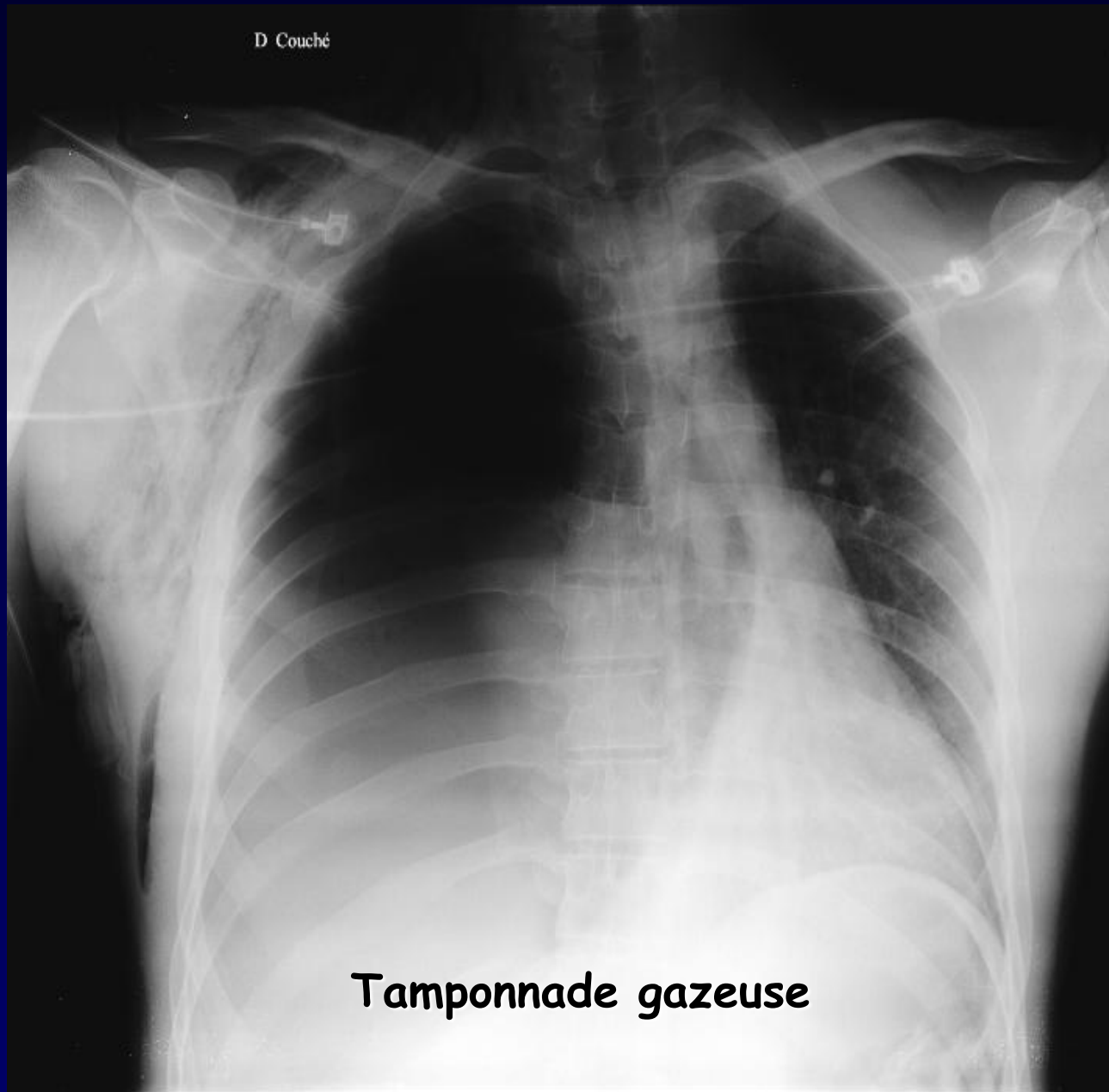

D Couché

Exsufflation - Rx CTRL : 17H37

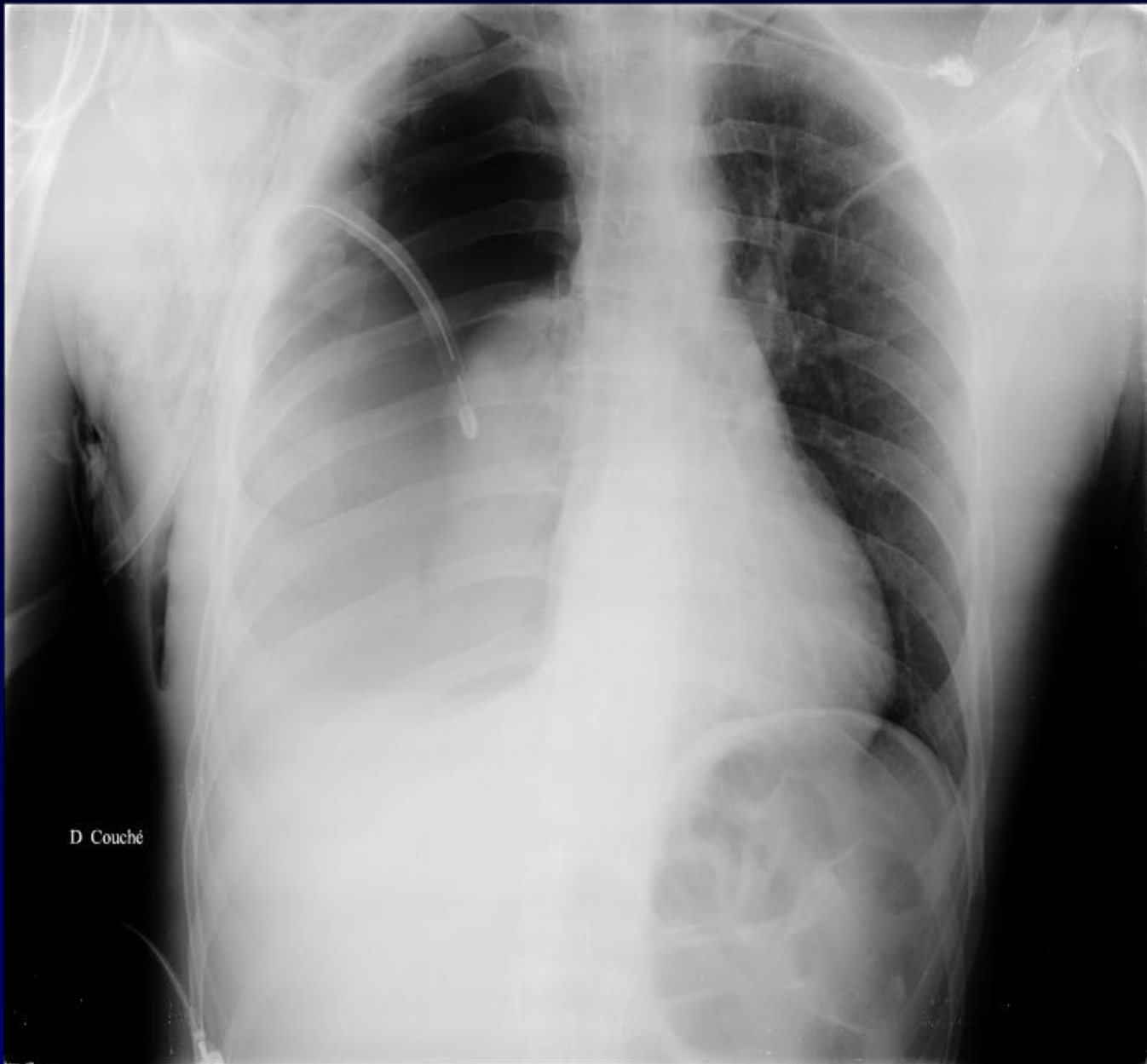


D Couché

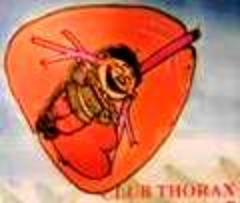

Tamponnade gazeuse

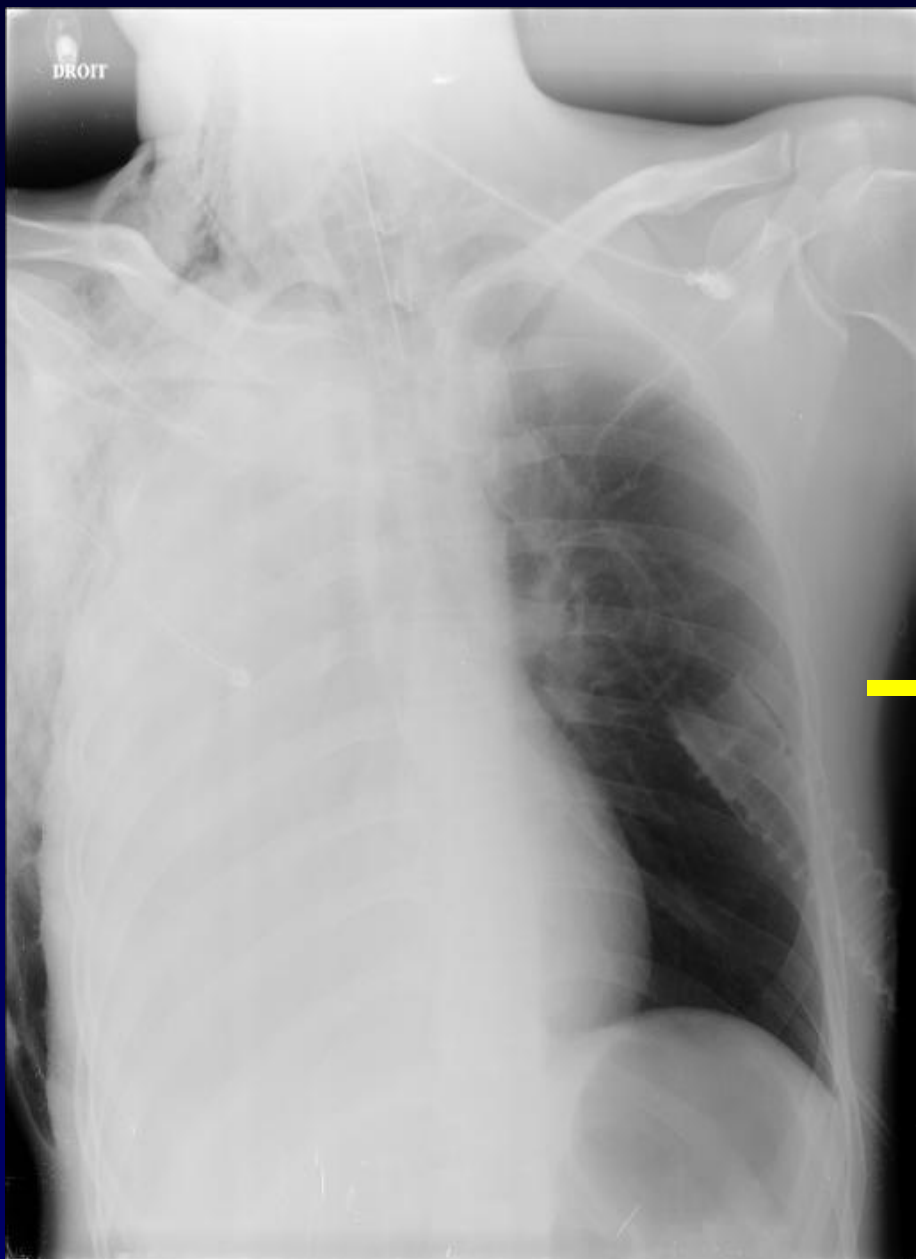
5H 35 min



6H 38 min



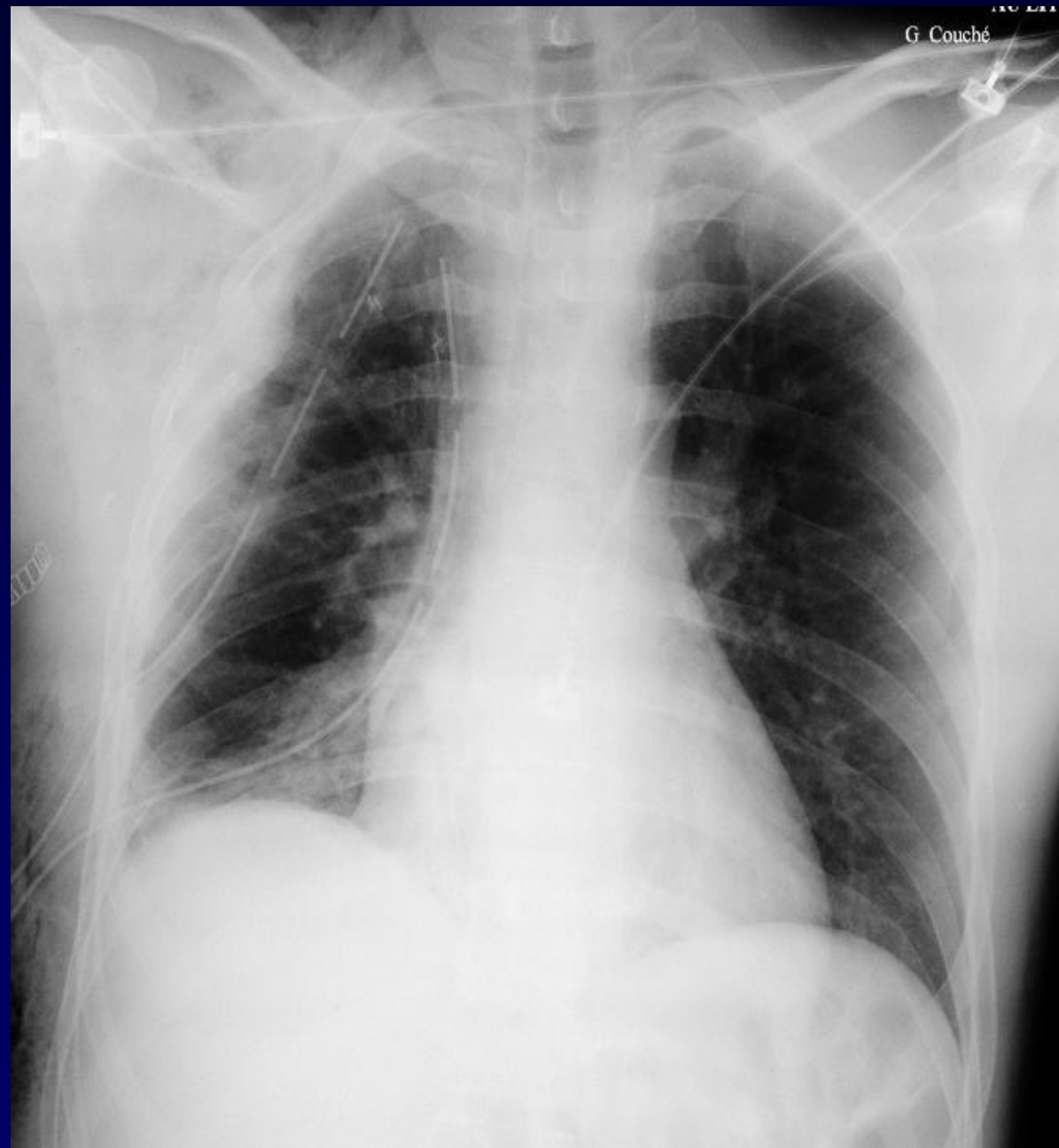8H 57 min



**Bloc
opératoire**

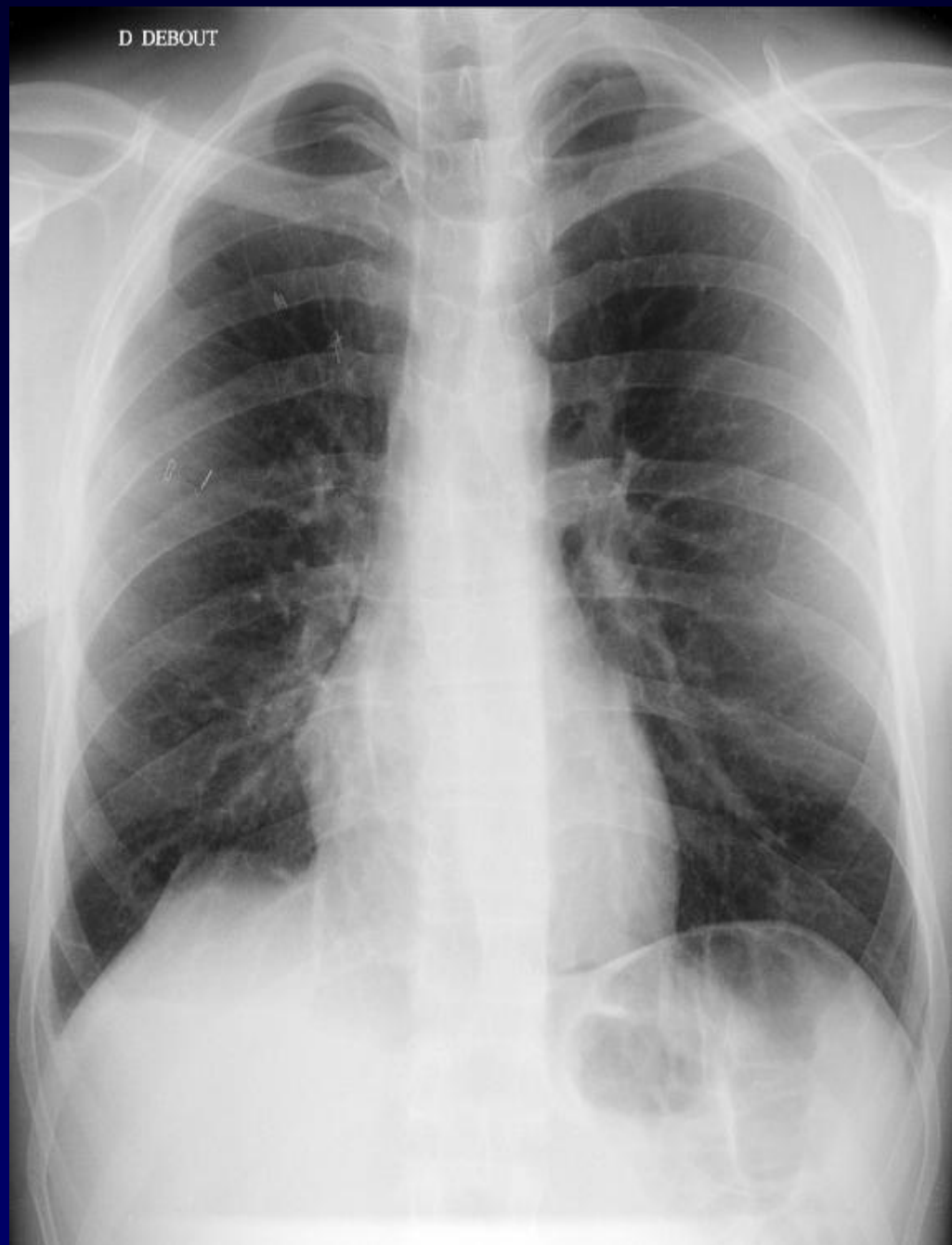

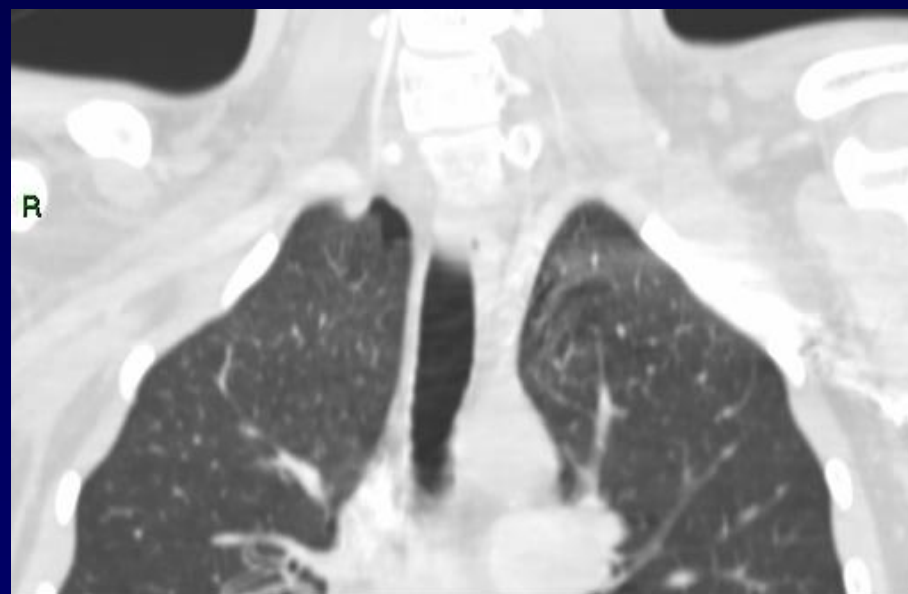
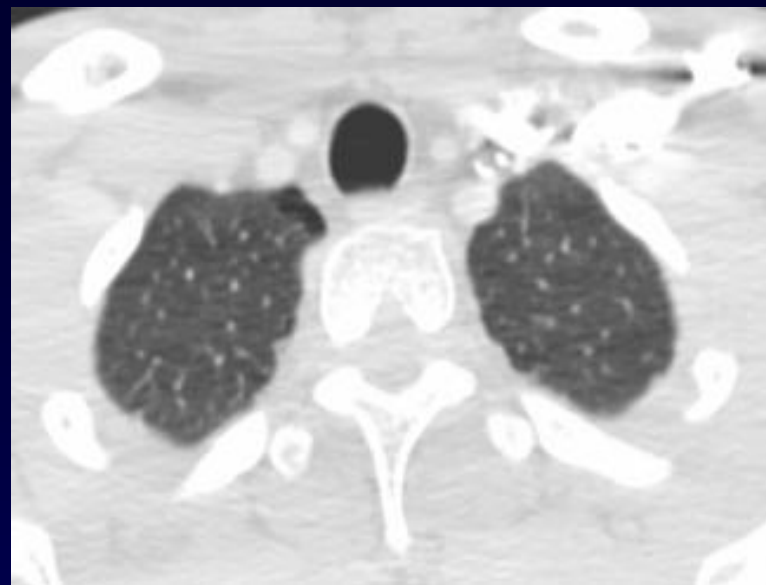
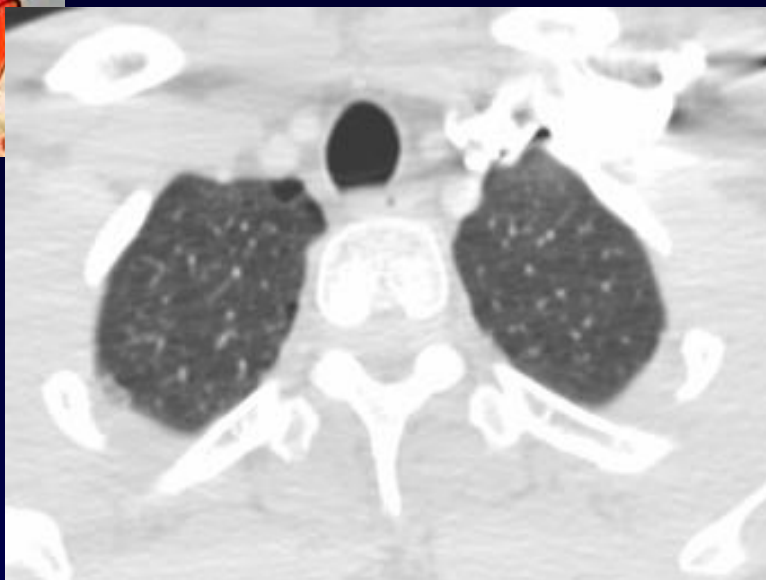
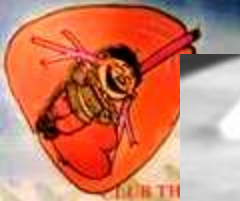**Rx post-
opératoire
13H 08 min**



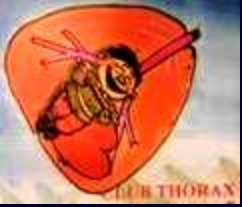

CTRL à J15





« Blebs » apicales



Discussion

Pneumothorax secondaire à la rupture de « Blebs »

Re-décollement pleural après exsufflation

Tamponnade gazeuse

Etat de choc hémorragique par rupture de bride pleurale

Hémostase chirurgicale

Evolution favorable